VOL XXVI, NO 3 JUNE 1994

TRANSPLANTATION PROCEEDINGS

An Official Publication of The Transplantation Society
The Japan Society for Transplantation • The Hellenic Transplantation Society
The European Society for Transplantation • The Canadian Transplantation Society
The Transplantation Society of Australia and New Zealand
The Scandinavian Transplantation Society • The Latin American Transplantation Society
The Pan-American Society for Dialysis & Transplantation • The Society for Organ Sharing
The Catalan Transplantation Society • The Asian Transplantation Society
The International Liver Transplantation Society • The Cell Transplant Society
The Middle East Society for Organ Transplantation • Société Française de Transplantation

Proceedings of the Second International Congress on

XENOTRANSPLANTATION

Cambridge, England
September 26–29, 1993

Guest Editors

DAVID COOPER
Oklahoma City, Oklahoma

EJVIND KEMP
Aarhus, Denmark

KEITH REEMSTA
New York, New York

DAVID WHITE
Cambridge, England

AND

Third International Symposium on

SMALL BOWEL TRANSPLANTATION

Paris, France
November 3–6, 1993

Guest Editor
YANN REVILLON
Paris, France



Publications Committee
H. Kreis, Paris, France *J. B. Otte, Brussels, Belgium*
Richard Wood, London, England

ALSO IN THIS ISSUE

Proceedings of the XVIIth Congress of the

SCANDINAVIAN TRANSPLANTATION SOCIETY

Copenhagen, Denmark
August 26–28, 1993

Chairman and Guest Editor
ARNE SVEJGARD
Copenhagen, Denmark

APPLETON & LANGE

Morphology of Acute Rejection and Observation of Lymphoproliferative Hyperplastic Reaction in FK 506 Treated Pigs After Small Bowel Transplantation

M. Spada, E. Arbustini, M. Alessiani, P. Morbini, C. Genovese, S. Vischi, M. Maestri, M. Merli, P. Dionigi, S. Todo, K. Abu-Elmagd, and A. Zonta

SMALL BOWEL transplantation (SBT) has become a clinical reality after the introduction of FK 506.[1] However, immune reactions, including acute or chronic rejection and graft versus host disease (GVHD), continue to be a major problem. Histological assessment by light microscopy represents the standard tool for monitoring SBT. The existing grading systems (GS) are based on different experimental models and immunosuppressive techniques, which are so different that the results are hardly comparable. We investigated the clinicopathologic outcome of SBT in FK 506 immunosuppressed pigs. The aims of the present study were (1) to identify the histopathologic profile of acute cellular rejection (ACR); (2) to assess the incidence of ACR with various FK 506 dosages; and (3) to detect immunosuppression-related complication.

MATERIALS AND METHODS

Study Group

Twenty-one healthy outbred piglets underwent total orthotopic SBT except for the duodenum and 5 cm of the terminal ileum. Intestinal reconstruction was performed with jejuneal side-to-side and ileal end-to-end anastomoses. A 10-cm segment of graft proximal jejunum was exteriorized as a jejunostomy for visual monitoring, postoperative (PO) mucosal biopsies (MB), and enteral feeding. Animals were divided into four groups according to immunosuppressive treatment: Group 1 (n = 3) received no immunosuppression (control group), group 2 (n = 5) was treated with FK 506 IM 0.1 mg/kg/d, group 3 (n = 5) was treated with 0.15 mg/kg/d, and group 4 (n = 8) was treated with 0.2 to 0.3 mg/kg/d. FK 506 trough plasma levels were determined with a fluorescence polarization immunoassay (FPIA, TDX-Abbot). Steroids were added in groups 2 and 3, whereas group 4 animals received only a postreperfusion bolus (500 mg IV). The present study includes 17 out of 21 animals that survived 9 days or longer.

Morphologic Studies

MB through the jejunostomy was performed on the 7th, 14th, 21st, and 28th PO days; moreover, full-thickness biopsies of the graft were obtained after reperfusion and at postmortem examination (PME). Formalin-fixed, paraffin-embedded samples were stained with hematoxylin and eosin and pentacromic Movat stain. The GS takes into account 48 different criteria to evaluate the histology of SBT (Table 1). According to these criteria, three different grades of ACR were identified: Severe ACR was characterized by diffuse haemorrhagic necrosis of the mucosa; moderate ACR was identified by short and broad villi, focal epithelial denudation, significant cellular infiltration, and lacteal enlargement; and mild ACR was defined by mild edema, some dilated lacteals, few slightly shortened villi, and initial cellular infiltration.

Table 1. Criteria Considered in the Morphological Study

Mucosal Villi	Lamina propria
Absent	Edema
Depleted	Stasis
Edema	Mononuclear infiltration
Narrow	PMN infiltration
Short	Hemorrhage
Broad	Muscolaris mucosae
Translocation	Stasis
Epithelium	Hemorrhage
Flattened	Splitted
Exfoliated	Mononuclear infiltration
Denuded	Disorganization
Necrosis: superficial	Submucosa and muscle layer
ischemic	Edema
Goblet cells: increased	Fibrosis
reduced	Collagen
lost	Cuffing
Connective tissue	Cellular infiltration
Edema	Vessel
Stasis	Leucocytic adhesion
Cellular infiltration	Thrombosis
Lacteals	Endothelialitis
Dilated	Cellular infiltration
Absent	Fibrinoid necrosis
Crypts	Nerves
Dilated	Swelling
Short	Cellular infiltration
Disorganization	
Degeneration	
Regeneration	
Abscesses	

RESULTS

Clinical Course and Survival

Observed mean survival time was 12 ± 1.4 days in group 1, 12.2 ± 3.5 days in group 2, 18.2 ± 1.5 days in group 3, and 27 ± 6.4 days in group 4. Causes of death and survivals are reported in other part of this issue.[2]

From the Department of Surgery and Pathology, University of Pavia Medical School, IRCCS Policlinico San Matteo di Pavia, Pavia, Italy; and The Transplant Institute, University of Pittsburgh School of Medicine, Pittsburgh, Pennsylvania.

Address reprint requests to Dr Mario Alessiani, Patologia Chirurgica I, Policlinico San Matteo, Piazza Golgi, 27100 Pavia, Italy.

0041-1345/94/$3.00/+0

Table 2. Incidence of the Different Grades of ACR in Each Group at MB and PME

Grade of ACR	GROUP 1		GROUP 2		GROUP 3		GROUP 4	
	MB	PME	MB	PME	MB	PME	MB	PME
Absent	—	—	—	—	—	—	40%	80%
Mild	—	—	—	—	50%	50%	60%	—
Moderate	50%	—	100%	75%	50%	50%	—	20%
Severe	50%	100%	—	25%	—	—	—	—

Histopathologic Findings

In all groups, histological findings after reperfusion showed edema with lacteal enlargement and focal epithelial cell loss at the villus tips. The incidence of the different grades of ACR in each group at MB and PME are summarized in Table 2. In group 1 MB showed moderate to severe ACR characterized by shortening of the villi with focal architectural upset, reduction and degeneration of the crypts, connective edema with cellular infiltration, and lacteals disappearance; PME revealed severe ACR with destruction of mucosal layer and muscolaris mucosae and massive cellular infiltration of the muscle layer. In group 2 most of BM and PME displayed a morphological picture of moderate ACR mainly characterized by shortening of the villi, flattening of the epithelium, dilated crypts, edema, and cellular infiltration in the lamina propria and muscolaris mucosae. In group 3 half of the cases showed features similar to those observed in group 2, whereas the remaining 50% of the cases showed only mild ACR characterized by lacteal enlargement and edema. In group 4 20% of the animals showed mild rejection, whereas the remaining 80% were rejection free. Moreover, in group 4, at PME, a focal lymphoproliferative hyperplastic reaction (LHR) of the intestinal graft was present in five of the seven cases (71.4%). In these latter cases, the graft was thickened and showed endoluminal polypoid vegetation. This finding was especially evident near the intestinal anastomoses. Microscopically we observed a lymphoproliferative hyperplasia localized in the submucosa, with sparing of the other layers; in the mucosa the epithelium was still present even if the villi were absent (Fig 1). No histopathologic signs of GVHD were detected in any group. FK 506 trough levels ranged from 0.4 to 3.2 ng/mL in group 2, from 0.5 to 13 ng/mL in group 3, and from 6.9 to 60 ng/mL in group 4.

DISCUSSION

The histological changes observed in the intestinal graft of the four different groups correlated with FK 506 trough levels. In humans, the therapeutic level ranges from 5 to 20 ng/mL. Clinical[1] and experimental experiences[3] demonstrated that intestinal recipients require higher FK 506 levels than other solid organ recipients to control the immunological reactions of the transplanted graft. Our study confirmed previous reports. With FK 506 levels at a low therapeutic range (group 2), ACR occurred within the same posttransplant interval of nonimmunosuppressed pigs. In addition, ACR showed similar histopathologic features in both groups. As the FK 506 levels were increased to a higher therapeutic range (group 3), ACR was milder and the survival time longer. Nevertheless, the incidence and morbidity of ACR remained unchanged. In group 4, the FK 506 plasma level monitoring documented a state of drug overdosage. An impressive decrease in

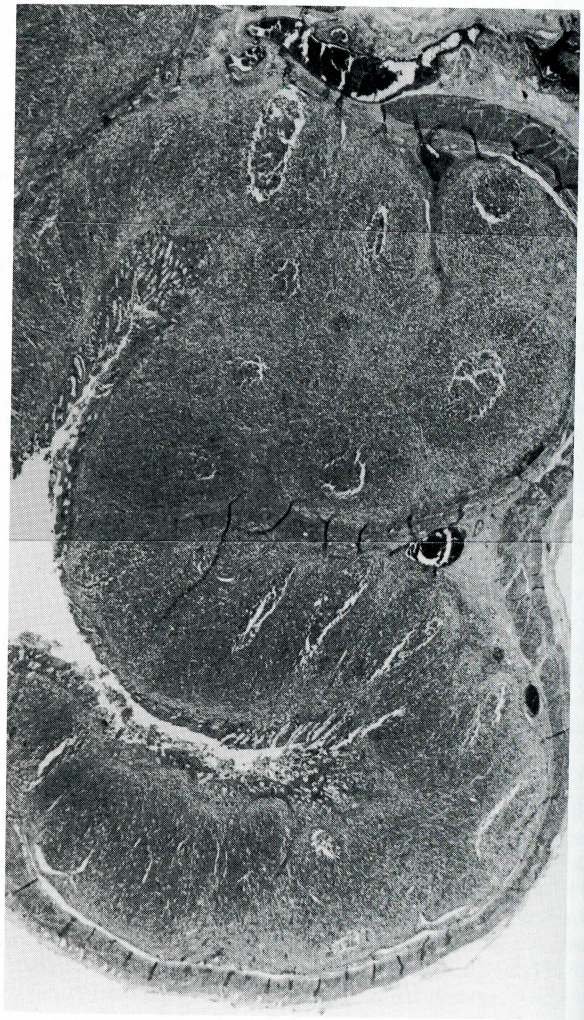

Fig 1. PME on the 22nd PO day; lymphoproliferative hyperplastic reaction, giving rise to suspicion of a posttransplant lymphoproliferative disorder (PTLD), involving the submucosa; the mucosal, muscolar, and serosal layers are noninvolved.

episodes of ACR occurred in this latter group, and the majority of the pigs were rejection free at time of death. Nevertheless, survival time, which ranged from 18 to 35 days, was affected by sepsis and emaciation. We are not aware of previous experimental studies reporting an LHR similar to that observed in 71% of the overimmunosuppressed pigs of group 4. The significance of the focal LHR seen in the intestinal graft is to be clarified. It suggests a posttransplant lymphoproliferative disorder (PTLD) because it occurred in a regimen of FK 506 overdosage.[4] However, the interval between SBT and death was too short to allow a PTLD to occur. In addition, no regional lymph node hyperplasia or similar lesion in the other organs was present. Another possible interpretation is that the lymphoid hyperplastic reaction is due to the intestinal stasis. This possibility has been suggested by Dr A.J. Demetris, who kindly reviewed our slides. Whatever the origin, this type of lymphoid reaction requires further investigation, including immunophenotypical characterization of lymphocytic cells and the search for lymphotropic virus DNA.

ACKNOWLEDGMENTS

The authors thank Dr A.J. Demetris, Director Division of Transplant Pathology, University of Pittsburgh Medical Center, for having kindly reviewed part of the histopathologic slides of group 4 animals.

REFERENCES

1. Todo S, Tzakis A, Abu-Elmagd K, et al: Ann Surg 216:223, 1992
2. Alessiani M, Spada M, Vischi S, et al: Transplant Proc, this issue
3. Yoshimi F, Nakamura K, Zhu Y, et al: Transplant Proc 23:3240, 1991
4. Nalesnik MA: Am J Surg Pathol 14(suppl 1):92, 1990